

33

Nail Surgery

JOHN E. LACO

Nail surgery can be divided into two basic categories: excision of the pathologic or undesirable tissue by use of sharp instrumentation, or destruction of the pathologic tissue by physical means such as chemicals, freezing, electrogalvanism, burring, or lasering. Currently, the procedures most popular and most regularly performed are chemical. However, laser surgery is gaining popularity because the public currently perceives laser surgery as being in vogue.

ANATOMY

It is important to understand the standard terminology used when examining the nail and performing nail surgery. Most terms are fairly common and easy to understand¹ (Fig. 33-1). When reviewing the literature, discrepancies are seen in the exact location of the nail matrix, which is a pivotal point in the success or failure of certain procedures. There seems however to be a general agreement as to the posterior location of the matrix.¹⁻⁷

As depicted¹ (see Fig. 33-1), some authors describe the nail matrix as having a "wrap-around characteristic"⁷ and therefore being located dorsal and plantar to the nail root. Others have depicted the nail matrix as being plantar or plantar and proximal to the nail root only. Anatomy text descriptions of the exact location of the nail matrix seem vague and nonspecific. It is suggested at this time that the low recurrence rate of chemical matrixectomies may be attributed to the fact that the nail matrix dorsal to the nail is destroyed by the nature of the procedure, which would lend support to the idea of a wrap-around characteristic of the nail matrix. Further studies specifically designed to

identify the exact location of the nail matrix and its nail borders must be performed.

DIRECT TRAUMA TO THE NAIL

Direct trauma to the nail from stubbing the toe or a falling object may lead to formation of a subungual hematoma. The subungual hematoma should be evacuated to relieve any pressure that may be being applied to the nail bed and causing the patient pain, as well as relieving any deforming force the hematoma may be applying to the nail itself. Wee and Shieber described using a red-hot paper clip to burn through the nail and decompress the hematoma, thus avoiding use of anesthetics and unnecessary discomfort to the patient.⁸ Palamarchuk and Kerzner⁹ describe using a hand-held cautery device for evacuation of subungual hematoma. If the podiatric physician has access to a laser, a small, precise portal of evacuation for the subungual hematoma can be created but this will require anesthesia because of the surrounding heat created.

I prefer using a large-bore needle in a rotating fashion to evacuate the hematoma. Minimal pressure is required to penetrate the nail, and anesthesia is usually not necessary. In cases of old subungual hematoma where coagulation has already occurred, a sterile burr may be used to deroof a portion of the nail over the hematoma so that a sterile curette or other instrument can be used to evacuate the coagulated tissue.

Direct trauma may also result in partial lysis or separation of the nail from the nail bed. Usually any type of pressure, such as the upper of a shoe will cause excruciating pain. It is recommended that a total nail avulsion be performed to relieve discomfort, prevent further traumatic onycholysis, and prevent

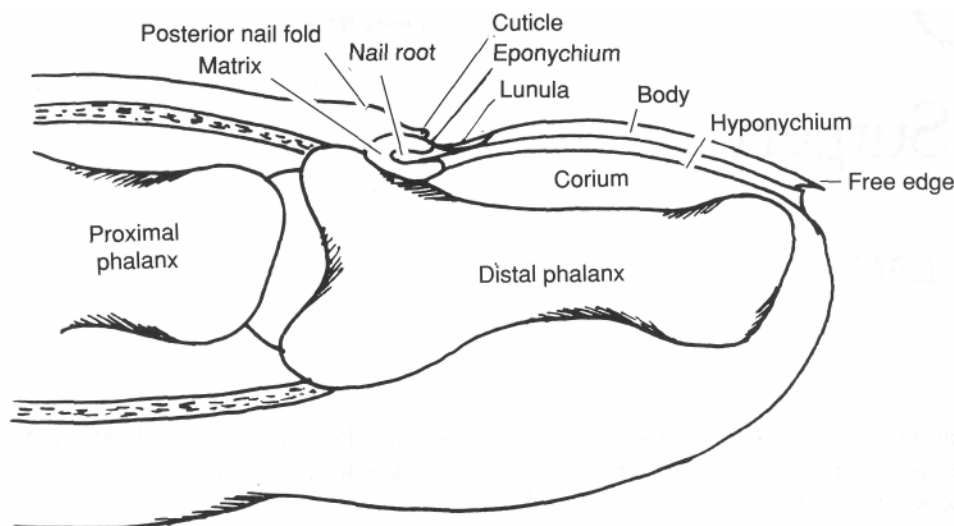


Fig. 33-1. Common terminology of nail anatomy. (Illustration by Marlene Burns.) (From Burns et al.,¹).

infection, because a lysed nail is no longer an effective barrier against microbes. Several techniques can be used to perform a total nail avulsion. After suitable prepping and anesthesia, a periosteal elevator or a flat spatula is used to separate the nail from the nail bed, as well as the nail plate from its dorsal attachments to the posterior nail fold. The nail may be avulsed with a hemostat. Forcefully removing the nail from the toe may fragment the nail and unnecessarily traumatize the nail bed and nail matrix. Therefore, adequate separation must be achieved before removal.

Albom recommends using a #24 or #24A dental spatula to separate the nail plate from the nail bed.¹⁰ Scher describes using a dental spatula and avulsing the nail in a proximal to distal manner.¹¹ Other variations include splitting the toenail in half with an English nail anvil and a #62 blade and avulsing the halves separately. Some clinicians prefer inserting a curved hemostat proximally between the nail plate and the soft tissue underneath the opening the jaws of the hemostat to avulse the nail. After avulsion of the toenail by any means, adequate care should be taken of the exposed area until healing is evident. A long-term follow-up appointment should be made to monitor re-growth of the new nail and prevent "shoveling" (Fig. 33-2).

ONYCHOCRYPTOSIS

Etiology

There are many theories on the etiology of onychocryptosis. Many authors believe improper debridement by the patient can lead to ingrown nails.¹²⁻¹⁵ Ill-fitting shoes may also be a causative factor.^{12,13,16,17} The presence of a subungual exostosis has been stated to be the pathogenesis,¹⁸ and excess soft tissue or soft tissue growing in excess has also been blamed as the etiologic factor for ingrown toenails.^{12,14,19-22} Hypermobility of the first metatarsal segment and hallux valgus have been indicated as etiologies of onychoc-

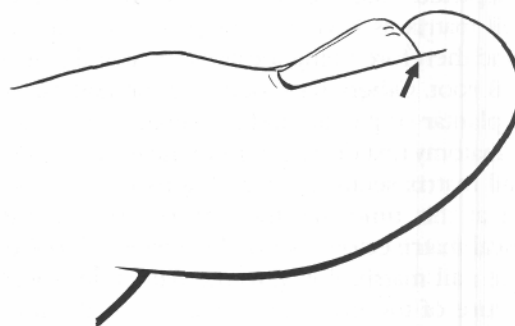


Fig. 33-2. "Shoveling" of distal aspect of nail.

Classifications

Cryptotic nails have been classified into types²⁴ or stages.¹² However, the ingrown nail is either symptomatic or asymptomatic and is either infected or noninfected. There are certain border presentations that vary from patient to patient, but treatments do not (Fig. 33-3).

The arc of the nail has much to do with symptomatology and infection, as the pathology probably increases with an increasing frontal plane arc of a nail (Fig. 33-4).

Paronychia

A paronychia is described as a local soft tissue infection surrounding the nail.²⁵ Onychocryptosis, if severe, will eventually puncture the skin and lead to soft tissue infection. If mistreated long enough, a local cellulitis may progress to systemic involvement with red streaks, swollen lymph glands, fever, and sepsis. Another sequela may be osteomyelitis of the distal phalanx, which will then require debridement and long-term antibiotics. Therefore, it is imperative that a swift and decisive treatment be performed immediately. Antibiotics and foot soaks alone are not adequate treatment to resolve the paronychia. The offending nail that has punctured the skin must be extracted through a partial or total nail avulsion.

A general guideline for treatment of paronychia is as follows. A total nail avulsion should be performed in the most extreme and chronic cases of paronychia,

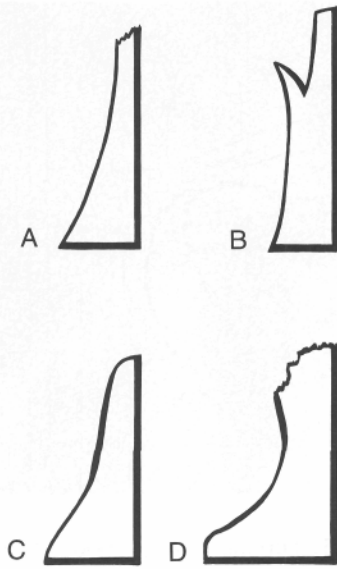


Fig. 33-3. Resected ingrown nail borders. (A) Wedged; (B) spiculated; (C) extended nail route; (D) combination.

cryptosis.²³ Other causes may be trauma to the nail matrix or nail bed, with a resultant dystrophic nail. Onychomycosis may allow the nail to thicken and grow abnormally, which may result in a cryptotic border. Probably one of the most common causes of paronychia from a cryptotic border is iatrogenic in nature (i.e., bathroom surgery).

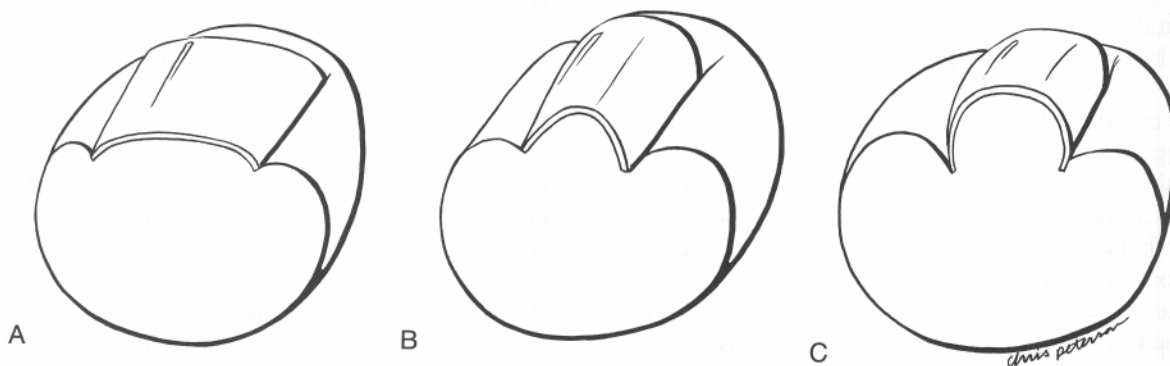


Fig. 33-4. Frontal plane arc of nails. (A) Normal arc; (B) moderate arc; (C) severe arc.

especially if the paronychia is of long-term duration. It may also be necessary to perform a total nail avulsion if the nail is dystrophic. Antibiotics in this case are required, along with local care in the form of antiseptic soaks, antiseptic creams, or both. If only one border is involved and inflammation and drainage is evident around the eponychium, an adequate strip of nail that includes the proximal aspect of the nail should be removed. Again, appropriate antibiotics and antiseptic local care are required. However, on the other hand, if paronychia is localized to the nail spicule itself and the nail spicule can be isolated, a partial oblique excision of the nail may be performed. Usually, local antiseptic care without systemic antibiotics will resolve this problem.

A radiographic study is indicated in chronic paronychia of long-term duration to rule out bony involvement, especially if the foregoing measures do not resolve the problem in a reasonable length of time. Also, a chronic unresolving paronychia may not be caused by an ingrown nail exclusively. A case in point is a young woman who presented to the office with inflammation to the distal one-half of the hallux for 2 years. The patient had seen many physicians, but none had taken radiographs. A foreign body was discovered of which the patient was unaware (Fig. 33-5).

At the time of the initial visit, the patient should be informed that there is a high probability of recurrence of the ingrown nail several months after resolution of the paronychia and that a permanent nail removal procedure is recommended in the future. The high recurrence rate for ingrown nails after avulsion is well documented in the literature.^{13,26,27}

The permanent removal of an ingrown nail should not be performed unless the paronychia is resolved. Many authors agree that the infection should be eliminated before performing a permanent nail procedure.^{2,17,27,28} In fact, postoperative sepsis has been reported as a complication when performing surgery on infected toes.^{2,28}

Another consideration in the resolution of paronychia is the health status of the patient. Prolonged recovery from a paronychia, high recurrence of paronychia, or multiple occurrences of paronychia may indicate an underlying disease process such as anemia, diabetes, or malnutrition. Of curiosity is the apparent increased rate of paronychia in women after pregnancy. Possible reasons for this may be anemias, edema, tight-fitting shoes, and "crash" diets.

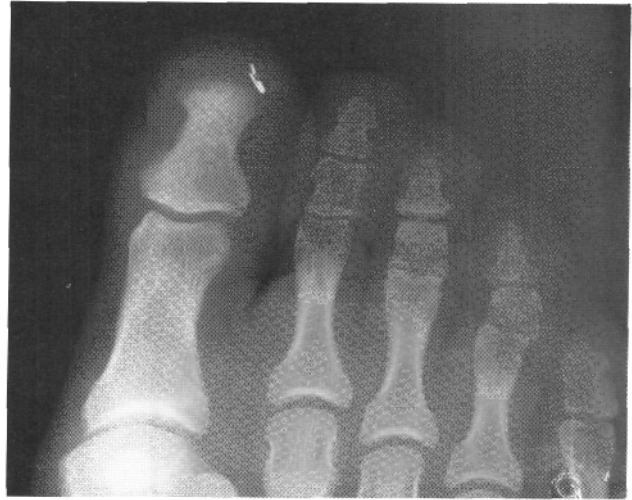

Fig. 33-5. Subungual foreign body of hallux.

Physical Modalities for Permanent Correction of Onychocryptosis

There are several methods using different physical modalities to destroy the nail matrix and correct onychocryptosis. Perrone reported using a high-speed, low-torque air motor with a Busch burr to "erase" the nail matrix.²⁹ This can be performed for partial or total eradication of nails. Silverman in 1984 described using a liquid nitrogen cryoprobe to destroy the germinal matrix after the nail border was removed.³⁰ Electrosurgery to treat ingrown nail pathology has been described by many authors.^{5,23,31-33} Interestingly enough, one of the mechanisms of destruction is by the production of sodium hydroxide.^{5,33} Although one postoperative study seemed to have promising results,³³ electrosurgery for treatment of ingrown nails is not performed on a widespread basis.

Devices and tools have been designed for treatment of onychocryptosis. In 1954, the Steinberg trephine was introduced for surgery of ingrown toenails.²⁸ A multitude of devices have been described, ranging from a toenail splint³⁴ to a surgically inserted nail plate²² to a wire brace³⁵ to a Teflon plastic strip glued to the toenail.³⁶ In 1979, the "gutter treatment" was described for treatment of ingrown toenails.³⁷ Unfortunately, the ease and success of other procedures have overshadowed such devices completely and most have fallen by the wayside.

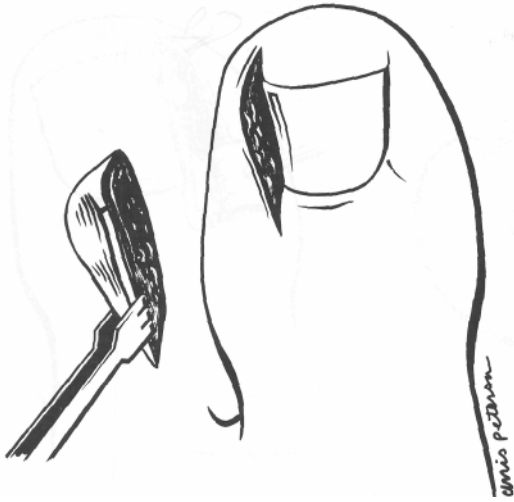


Fig. 33-6. Winograd procedure. A pie-wedge incision is used to resect the offending nail plate, nail bed, nail lip and nail matrix. (From Mercado,³⁸).

Wedge Resections for Permanent Treatment of Onychocryptosis

Winograd Procedure

The current concept of the Winograd procedure in podiatry is a wedge resection that includes the nail lip^{25,38} and is indicated for onychocryptosis along with a hypertrophied or overlapping ungualabia.¹ In the original procedure described by Winograd, the soft tissue around the margin of the ingrown nail is retracted and preserved.^{39,40} A current description of the Winograd procedure is that the nail is split longitudinally and an incision is made down to the bone through the split that extends proximal to the eponychium and distal to the nail itself.³⁸ A second incision is performed that is semielliptical and is deepened to bone. A wedge resection is then performed. Elements of the wedge are therefore nail plate, nail bed, nail lip, and nail matrix. The periosteum is removed by rasping and the nail lip remodeled before closure (Fig. 33-6).³⁸

Frost Procedure

Although the original Frost procedure was described in 1950,¹⁷ it still maintains a high degree of popularity. The description of the Frost technique from 1950 and

1957 is as follows.^{17,24} The entire nail is split at the point where the incurvated nail begins its arc. A vertical incision is then made down to but not into the phalanx and extending beyond either edge of the nail. The inverted L is created by making an incision 90° to the proximal end of the first incision. This incision should be through the dermis but not into adipose tissue. A flap is then underscored and created, taking care not to include any white, fibrous, glistening soft tissue, because this may indicate the nail root. A third incision is made parallel to the first, starting under the flap and extending distally. This incision becomes semielliptical as it courses to join the first incision at the distal aspect of the toe. The section of the nail, nail bed, and root is excised. Care is taken not to damage the periosteum. The area is inspected for white, glistening fibers, which are excised before the flap is replaced. No suturing is recommended, according to Frost (Fig. 33-7).

The indications for a Frost procedure are onychocryptosis; some clinicians do not advocate its use with a concurrent hypertrophic nail lip³⁸ while others do.¹

Phenol and Alcohol Partial Nail Matrixectomy

The most popular and widely used permanent correction of onychocryptosis in the United States is the phenol and alcohol partial nail matrixectomy.

The advantages of this procedure far outweigh its disadvantages of the advantages of other permanent partial nail corrections. The most obvious advantage is the success rate. Gallocher reports a success rate of 98.5 percent.⁴¹ Suppan and Ritchlin report a success rate of 98.7 percent,⁴² while Robb and Murray report a recurrence rate of 5 percent. Another advantage is lack of postoperative discomfort.⁴³⁻⁴⁵ Most patients do not require a prescription for postoperative pain, and if discomfort is experienced over-the-counter headache medication will usually suffice. Surgical excision procedures, on the other hand, usually require narcotic analgesics. It has been suggested that the neurolytic action of phenol is responsible for the decreased postoperative pain.⁴⁵ One major advantage is lack of disability after the procedure. A patient can usually return to work the same day without losing time from the job. Another advantage is cosmesis. There are no incisions into the skin and therefore no scarring occurs. The

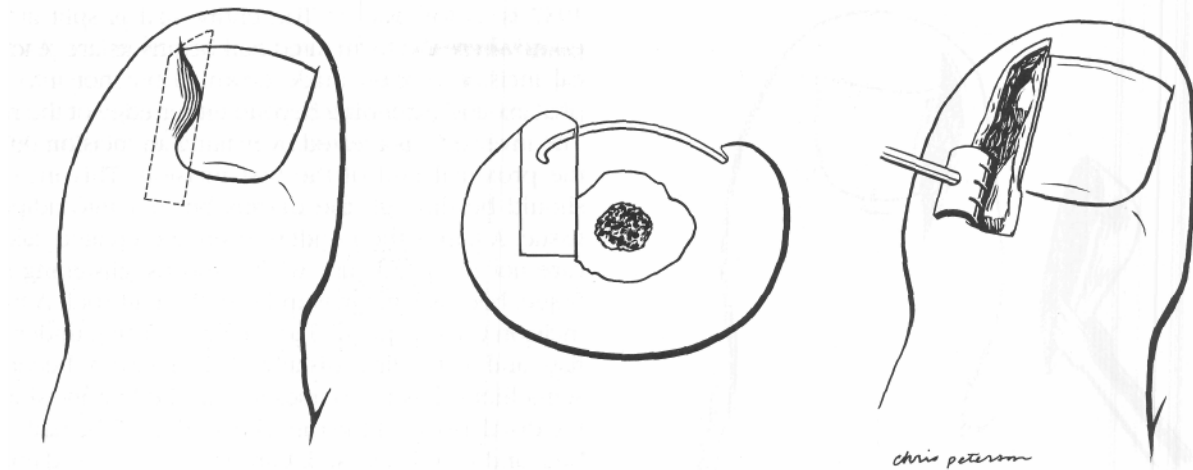


Fig. 33-7. Frost nail procedure. (From Frost,²⁴).

procedure is easily performed in an office setting with basic podiatric instruments.

One major disadvantage of this procedure is prolonged healing time⁴⁶ and therefore prolonged post-operative care. The phenol is a weak acid and therefore produces a burn. The normal process of healing is an immediate inflammatory reaction and a wound that must drain adequately before final healing occurs. Another disadvantage is that if a patient has a hypertrophic nail lip, plastic remodeling is not part of the procedure. Some clinicians have stated that the procedure is indicated where there is no significant or gross hypertrophy of the ungualabia.^{1,42} Some authors believe that a thin, cornified, epidermoid layer secreted by the nail bed after nail matrix destruction may be mistaken for nail plate,^{2,12} and this is in fact sometimes observed after phenol and alcohol matrixectomy procedures.

Description of Procedure

The phenol and alcohol partial matrixectomy procedure has been described on several occasions.^{42,43,46-48} After suitable prepping and anesthesia, a penrose drain is applied around the digits for hemostasis. Used here to prevent excessive bleeding and dilution of the phenol, which may cause a recurrence, a penrose drain must always be used with discretion as it is contraindicated in patients with impaired circulation. The

nail is split where desired with a nail nipper and onychotome or an English nail anvil. The nail is split under the eponychium with a #61 or #62 blade along the longitudinal striations of the nail. This is a very important point as the nail grows in this direction and if the nail split is not parallel to the striations of the nail, an excessive regrowth of nail may occur that is not anticipated (Fig. 33-8). Note that an English nail anvil will leave a perfectly straight edge of nail but if applied to the nail too far proximally will allow a separation of the nail plate from the nail bed or nail matrix on the desired new nail border. This occurs because of the wedged shape of the lower jaw. This can allow phenol to penetrate into the new nail border bed and matrix areas and create irregularities in the nail border that appear months later.

After the nail is split completely, a spatula or periosteal elevator is used to undermine the nail section to be removed. Once again, it is advised to undermine the nail after the nail is split so that unnecessary undermining of the new nail border is not performed. This is to avoid phenol penetration in those areas and unnecessary damage to the new matrix or nail bed, which may lead to unnecessary border irregularities or lysis of a nail plate, respectively.

A hemostat is used to grasp the nail completely and under the eponychium. The nail is removed by rolling the hemostat to the center of the nail. Removal of the nail should not be forced with the hemostat. Undermining procedures should be repeated again as tear-

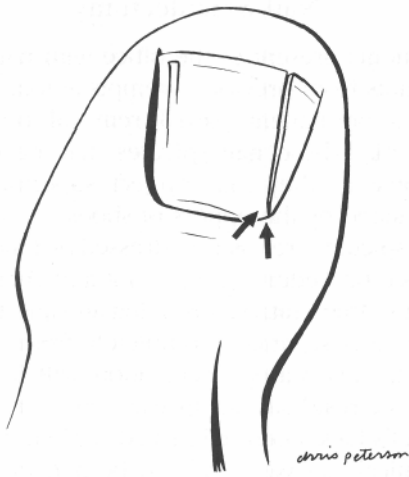


Fig. 33-8. Improper splitting of nail for phenol and alcohol matrixectomy. Arrows depict nail matrix not destroyed by phenol. Original border will return.

ing the nail spicule out may fragment the nail spicule and cause unnecessary recurrences. If care is used, an eponychial envelope will be created and the phenol will be applied exactly to the desired areas of destruction. Fibrous tissues are then resected with a curette and tissue nippers, and 85 percent phenol is applied by cotton-tipped applicators, cotton pellets, or with cotton rolled on toothpicks. A handmade toothpick applicator is usually applied for 30 seconds; this is repeated two times. Variations within this time will occur as different applicators vary in the amount of phenol delivered to the desired area of destruction.

Many experienced clinicians will apply phenol by sight as it will burn the tissues and appear white. Many clinicians will also coat the eponychium with a cream or ointment to prevent phenol burn; however, if phenol is applied meticulously, only small amounts of phenol will contaminate the eponychium. The small amounts of phenol contamination can be removed with sterile gauze. If the phenol applicator is indiscriminately contaminated with ointment or cream, the medication may enter into the nail matrix area, prevent destruction of the nail matrix by the phenol, and therefore provide another reason for recurrence.

After phenol application, the area is flushed with alcohol, the tourniquet released, and appropriate sterile dressings applied, usually after antiseptic applica-

tion of the clinician's choice. Unfortunately, as pointed out by Greenwald and Robbins, no chemical reaction occurs between isopropyl alcohol and phenol under the condition of a matrixectomy and therefore neutralization refers to a physical or mechanical dilution.⁴⁹

Complications

Complications are recurrence of the nail spicule. As seen from the previous discussion, poor technique may result in recurrence. It should be stressed that phenol does have an expiration date and therefore the date should be checked as this in itself may cause a recurrence. Other complications include losing the whole toenail when performing a bilateral nail border resection. This is especially true with indiscriminate use of the English nail anvil, unnecessary trauma or poor technique, or if the nail is thickened and dystrophic.

A patient may have an acute reaction to the phenol with resulting phenol burn. According to Yale, careless application may result in Beau's lines.⁴⁸ Phenol should never be manipulated near the patient as splattering droplets of phenol may burn the integument.

Formation of an abscess may occur after the phenol and alcohol matrixectomy procedure. It is not an infection per se, but emulates an infection because of increased inflammation and expression of purulent drainage on curettement. The abscess is usually very painful. It is postulated that the distal eponychial border forms an eschar and does not allow proper drainage of the phenol burn from an eponychial envelope proximal to it. It is recommended on postoperative visits that a curette or spatula be inserted in the area of the destroyed nail matrix to ensure adequate drainage. Also, during soaking, the patient may massage the eponychial dorsally to prevent premature closure of the eponychium border. These abscesses usually resolve within a few days after debridement and adequate soaking.

Postoperative Care

Postoperative care varies from clinician to clinician. A straw-colored exudate is expected to drain from the operative site^{43,44} and may persist for several weeks. The immediate postoperative response is one of intense inflammation that can certainly have the appearance of an infection. Debridement of the area is a key

point to prevent infection. The necrotic, sloughing tissue should be removed on a regular basis to prevent a medium for microbial growth. Also, as mentioned earlier, the eponychial envelope should be cleared of debris to allow for proper draining. If debridement is not performed regularly, a plug of escharotic tissue and callus may form in the nail groove and be as painful as the initial ingrown nail.

Many topical agents have been studied to treat the postoperative phenol and alcohol partial matrixectomy procedure. Some agents that have been reported in the literature are Debrisan,⁴⁶ Chymar,⁵⁰ and Travase.⁵¹ Combinations such as aqueous Zephiran 1:750 solution, metiderm aerosol, and Elase ointment⁵² for use immediately after surgery have been reported. Other favorites in this country include Cortisporin otic solution,⁵³ Silvadene, Neosporin powder and cream, Furacin, and betadine. As noted by Greenwald and Robbins, postoperative creams may be more beneficial than ointments⁴⁹ because creams do not inhibit drainage as do petroleum-based waterproof ointments. It is suggested here that if topicals are applied by the physician or patient, probably the most beneficial is a combination of antibiotic cream with an anti-inflammatory steroidal agent. This will provide prophylaxis as well as decrease the intense inflammatory response elicited by the phenol.

More important than topical agents used by the patient are foot soaks. Various agents include normal saline, Domeboros soaks, Epsom salts, tea soaks, betadine and water, vinegar and water, Pedi-boro soaks, and warm soapy water. These soaks will form an ionic solution that should assist in the drainage process. I personally prefer to have the patient begin with betadine soaks; the article by Ranaldi et al. specifically points out reduction in bacterial proliferation after matrixectomy using topical betadine microbicides.⁵⁴ After the initial inflammatory reaction has occurred, the patient is switched to a household product such as warm soapy water to enhance patient compliance as well as avoid irritation of the skin from betadine. It should be noted that the detergent Dreft be suggested to the patient if advising soapy water soaks. Because Dreft is specifically designed for laundering baby diapers, many allergenic agents found in other soaps are purposely avoided in the manufacture of this product.

Nail Spiculectomy

Many patients present to the office with nail spicules or remnants from previous attempts at total nail ablation or a permanent partial removal of the onychocryptosis. These nail spicules may be especially bothersome as they may project superior and become irritated by the uppers of shoes.

These spicules are easily addressed by following the same basic procedure of a phenol and chemical matrixectomy. After suitable prepping and anesthesia, the nail spicule is separated completely from soft tissue using a spatula. Careful separation will identify the "pocket" of residual nail matrix cells. After the nail matrix cells have been delineated, a phenol and alcohol chemical matrixectomy may be performed.

Postoperative visits are important to prevent early closure of the eponychium and abscess formation, as discussed earlier. Most patients are pleased with the results and the procedure itself, as many nail spicules are the results of inadequate sharp tissue resection and can be performed in the office with minimal postoperative pain.

Partial Phenol and Alcohol Matrixectomy for an Intractable Calloused Nail Groove

Of special interest is the use of a phenol and alcohol partial chemical matrixectomy for treatment of a heloma durum on the lateral nail border of an adducto varus fifth digit (Fig. 33-9).

With such a deformity, it is possible to remove a portion of the nail and prevent recurrence of the heloma dura. However, radiographs should be taken to rule out a bony exostosis on the distal phalanx as a cause of the heloma durum, and a clinical evaluation and discussion with the patient should occur regarding possible derotation of the fifth digit. Admittedly, a derotation of the fifth digit may be advisable, but the patient may not desire that extent of surgery or be able to afford time away from work or any debilitation whatsoever during recovery. It should be pointed out that the patient's chief complaint is the heloma dura on the lateral aspect of the fifth nail and not the adducto varus twist of the fifth digit. This procedure has been performed several times, and the patients seem to be pleased with the results.



Fig. 33-9. Heloma durum lateral nail groove of adducto varus fifth digit.

Sodium Hydroxide Chemical Matrixectomy

The sodium hydroxide chemical matrixectomy is performed in essentially the same manner as the phenol and alcohol matrixectomy procedure, but sodium hydroxide is used instead of phenol and acetic acid rather than alcohol. Destruction occurs by liquification necrosis⁴ and a true chemical neutralization takes place⁴⁹

Brown applies a 10 percent sodium hydroxide solution with a thinned out cotton-tipped applicator two times for a total of 20 to 25 seconds using pressure for hemostasis and neutralizing with a 3% solution of acetic acid.⁵⁵ Travers and Ammon obtain hemostasis with Lidocaine with Epinephrine 1:200,000 or 1:300,000 which allows visualization of the capillaries as they coagulate.⁴ They apply cotton pellets with 10% sodium hydroxide solution for 3 seconds to 3 minutes, "until the capillaries of the nail bed visually coagulate." They use a 5% acetic acid solution for neutralization. Sodium hydroxide chemical matrixectomy would probably be more common if the phenol and alcohol matrixectomy were not already an established and popular procedure.

Advantages

The advantages of the sodium hydroxide chemical matrixectomy over the phenol and alcohol chemical matrixectomy procedure are decreased drainage and

therefore decreased recovery time. Also, there seems to be less chance of a violent reaction using sodium hydroxide as opposed to using the phenol (personal communication, Dr. Tom Silver).

Laser Treatment for Ingrown Nails

The use of the laser for ingrown toenails has received a lot of public attention. The CO₂ laser produces an infrared light that is selectively absorbed by water and tissues, and the tissue is vaporized as the light is converted into heat energy.⁵⁶ Borovoy et al.⁵⁷ report the advantages of a laser as being precise control of depth and extent of the surgical site, as well as sterilization and cauterization.

The problem with laser surgery for onychocryptosis is that the laser beam itself is a straight line and adequate exposure of the matrix is difficult as it is not completely visualized with resection of the nail strip. This may lead to unnecessary destruction of the periosteum and "burning of the bone." Some clinicians will laser the eponychium over the matrix, which again leads to unnecessary destruction. Also, the laser beam will produce a zone of necrosis as the cells adjacent to the vaporized cells are heated to high temperatures. One possible suggestion is to make a small incision in the eponychium so retraction and visualization of the matrix can be attained without unnecessary destruction of soft tissue and bone.

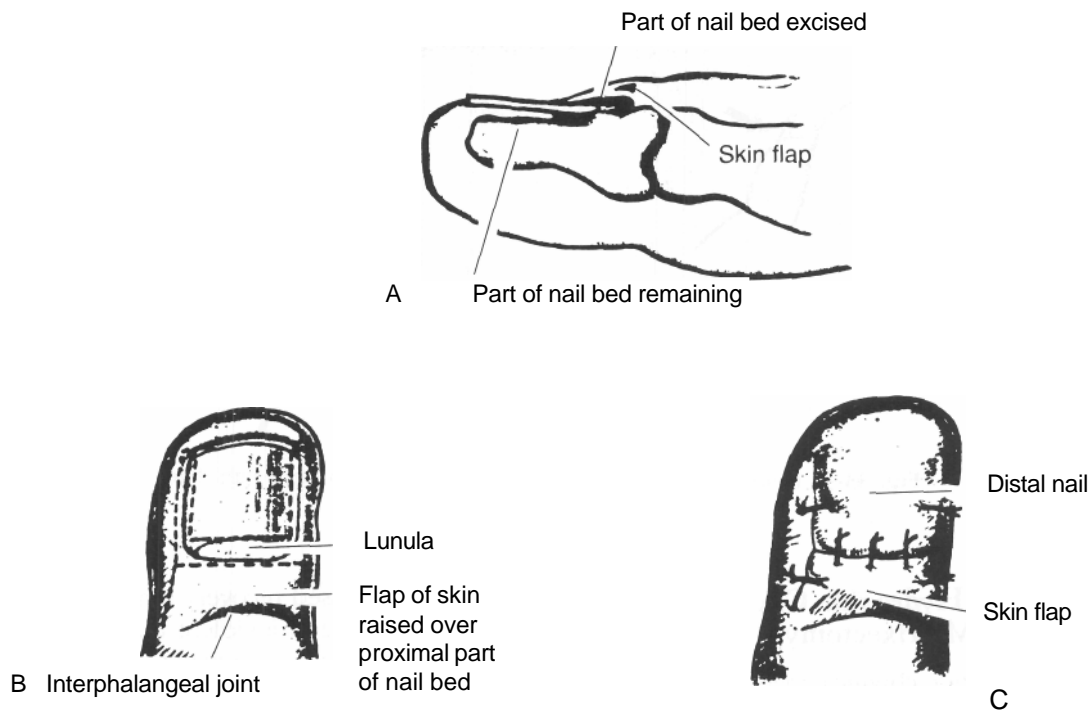


Fig. 33-10. (A-C) Zadik procedure. (From Zadik³).

Permanent Total Nail Removal

Permanent total nail removal may be advocated in onychogryphosis, onychomycosis, dystrophic nails, and continually recurring cryptotic borders. Trauma to the nail specifically may result in a need for a permanent total nail removal. A deformed nail may be caused by damage to the nail bed or nail matrix.⁷ Many partial permanent nail removals discussed earlier may also be used in total nail ablation, including onychotripsy,²⁹ CO₂ surgical laser,⁵⁷ phenol and alcohol chemical matrixectomy, and sodium hydroxide chemical matrixectomy. It should be stated once again that a proper and extensive patient history and physical examination be performed to identify high-risk patients such as the vascularly impaired, or the patient who presents with decreased peripheral sensation, relates a history of healing slowly, and then reveals a random blood sugar that is abnormally high. Unfortunately, repeated palliation may be the only choice of treatment. Urea ointment formulations for nonsurgical

avulsion of nail dystrophies⁵⁸ may also be an option. A double scrub before and after nail avulsion to decontaminate subungual tissues has been suggested,⁵⁹ and may be prudent, especially if sharp matrix excision is performed.

Zadik Procedure

A true Zadik procedure involves creating a skin flap, avulsing the nail, and resecting the nail bed proximal to the border of the lunula.³ The flap is advanced and sutured to the nail bed without tension. According to Zadik, the lateral nail folds are excised and corresponding coaptation with sutures is performed if the lateral nail furrows are deep. As with certain other total nail ablation procedures, nail bed resection is directed proximally and the nail bed distal to the lunula is undisturbed (Fig. 33-10).

Varying reports of success reveal numbers as low as 16 percent symptomatic recurrence rate for onychocryptosis,²⁷ to a recurrence rate as high as 28 percent²⁶ or a 29 percent symptomatic recurrence rate when

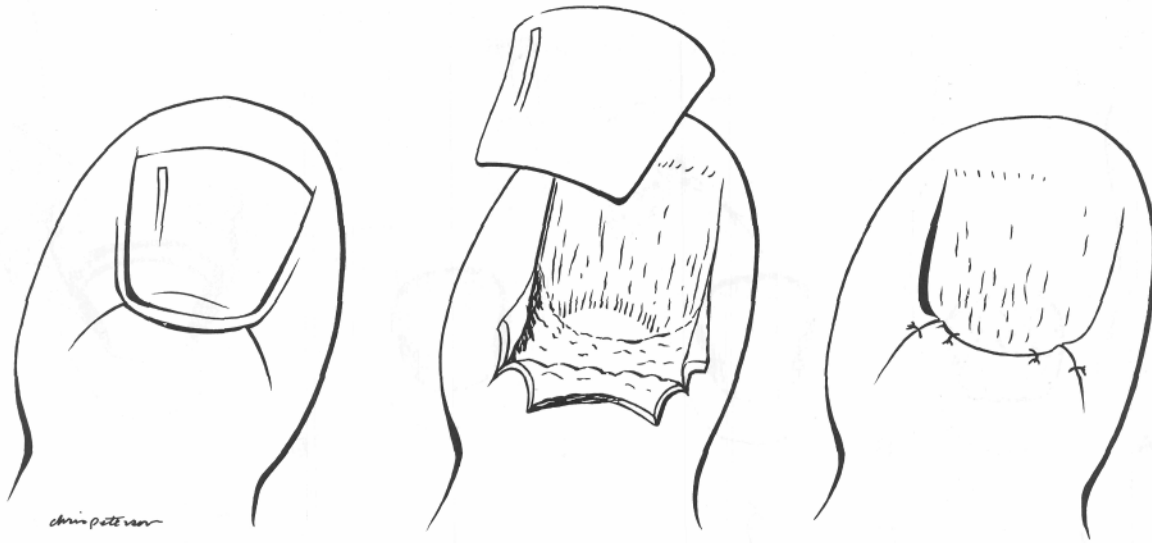


Fig. 33-11. Fowler procedure. (From Fowler²).

performed on children with nail dystrophy of the hallux.⁶⁰

Fowler Procedure

Fowler described a procedure of onychogryphosis and "bilateral embedded nails" where three flaps are created to expose the germinal matrix² (Fig. 33-11). Three recurrences of nail growth were reported in 50 operations for onychogryphosis.

Kaplan Procedure

In 1960, Kaplan published a procedure for total permanent nail avulsion in which no failures occurred in 369 cases.⁶¹ The Kaplan procedure is performed as follows. After proper surgical preparation, the great toe is anesthetized and the nail avulsed. The foot is prepped and a tourniquet applied. Two 1.5-cm incisions are made in the medial and lateral aspects of the posterior eponychium and extended proximally. Sharp dissection "at the nail level depth" is performed to expose the nail matrix. Another incision connects the nail folds at the distal end of the toe. The entire nail bed including the matrix is removed from the phalanx using sharp dissection. Exposed exostoses are resected, and the eponychial flap is replaced and sutured.

Other modifications regarding the procedure have been reported.⁶² Advantages of the Kaplan procedure are easy accessibility to the subungual exostosis if present, but disadvantages include wound healing by second intention or granulation tissue.

Whitney Acisional Matrixectomy

A Whitney "acisional" total matrixectomy procedure involves two "Frost incisions" for exposure and resection of the nail matrix.⁵⁹ After nail avulsion, the nail bed proper is not routinely resected (Fig. 33-12).

Suppan Nail Technique No. 2

To understand the technique behind the procedure, it is important to review Weisfeld's conception of the sagittal location of the nail matrix.⁷ The nail matrix has a "wrap-around characteristic" (Fig. 33-13). This "envelope" is to be excised. A brief summation of the procedure as described by Weisfeld, referred to as the "Suppan Nail Technique No. 2," is as follows.

After proper prepping, anesthesia, and hemostasis, the nail is avulsed. The remaining areas of hyponychium are debrided to prevent postsurgical recurrence. A #15 blade is placed parallel to the corium at the medial margin of the posterior nail fold and the blade is kept just deep to the nail fold. The blade is drawn

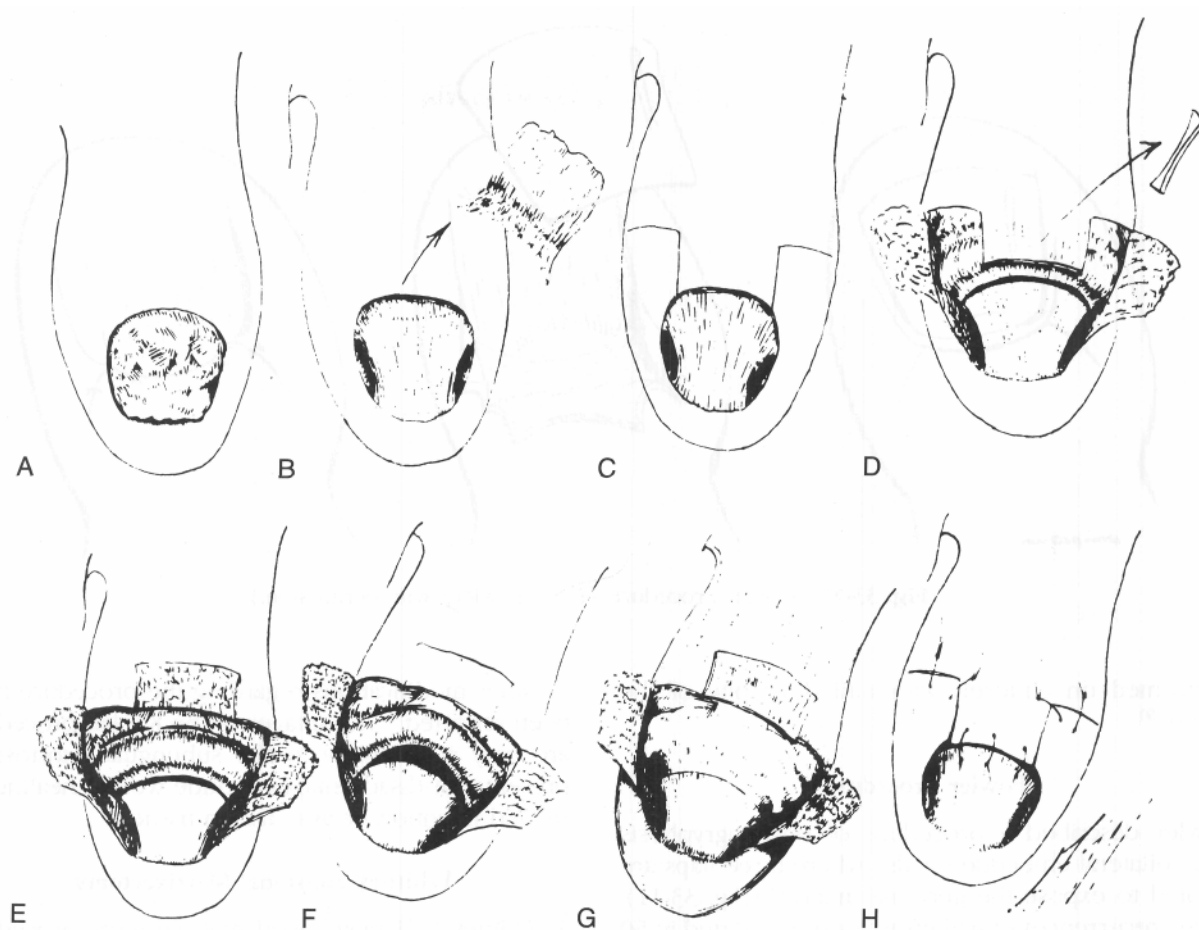


Fig. 33-12. (A-H) Whitney acisional matrixectomy. (From Whitney⁵⁹).

laterally over the entire matrix (Fig. 33-14) and angled plantarly against the bone at the medial and lateral aspects of the incision. A transverse incision is made down to bone at the nail matrix and corium junction with the blade angled somewhat posteriorly. The matrix is resected in toto. The posterior nail fold may be sutured to the bed, after inspection and removal of any remaining matrix tissue. Obvious advantages of this procedure are that no skin incisions are made.

Terminal Syme Procedure

Review of the literature reveals recurrences of ingrown nails to some extent, regardless of the procedure. One case report revealed the "ultimate solution"

as amputation for a "physically distorted toe and hypertrophied toenail that has become inflamed, painful, and disabling."⁶³ In 1933, Lapidus described complete excision of the nail and its associated structures with removal of approximately one-half of the distal terminal phalanx⁶⁴ (Fig. 33-15).

Many modifications of the procedure have been described. Permanent removal of the nail with partial amputation of the distal phalanx has become known as the terminal Syme procedure. Indications for the procedure include onychocryptosis, subungual osteoma, onychia, glomus tumor, circulatory dystrophies, mallet toe deformities, and macrodactyly.⁶⁵

With the advent of other techniques and specialized training, the terminal Syme procedure is usually re-

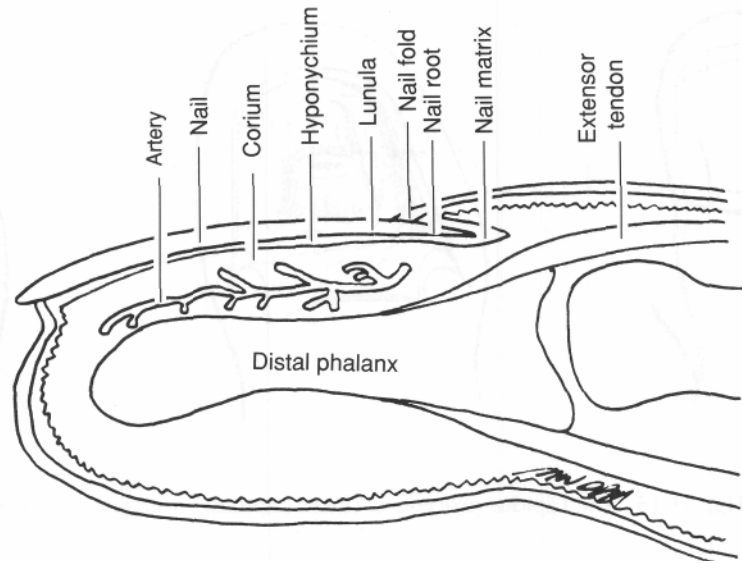


Fig. 33-13. Nail depicting “wrap-around characteristic” of the nail matrix. (From Weisfeld⁷).

served for special cases and not done routinely for recurrent ingrown nails.

TOTAL NAIL AVULSION FOR TREATMENT OF ONYCHOMYCOSIS

Onychomycosis is a constant complaint in the podiatrist's office. Current treatments have led to limited success, if any. Application of topical antifungals for treatment of onychomycosis in general does not work. Oral antifungals have had some success, but the medication has to be taken for prolonged periods of time, and the patient must be monitored clinically and with laboratory tests to avoid possible serious side effects. However, in 1991 Hettinger and Valinsky reported very encouraging results for treatment of onychomycosis by nail avulsion and daily topical application of ketoconazole cream.⁶⁶

Many clinicians have begun to avulse the nail, apply antifungal topicals to the nail bed and matrix, and begin an oral antifungal regime. This should resolve the onychomycosis in a shorter time period, increase the

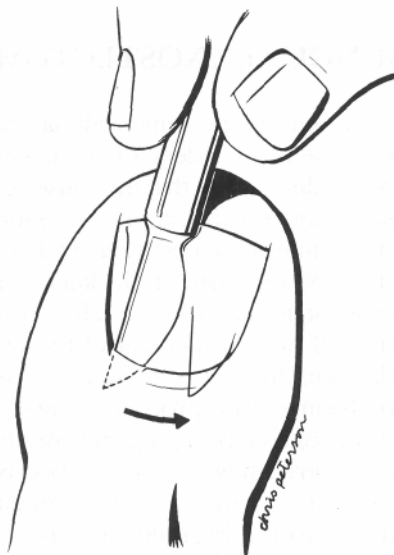


Fig. 33-14. Suppan nail technique no. 2.

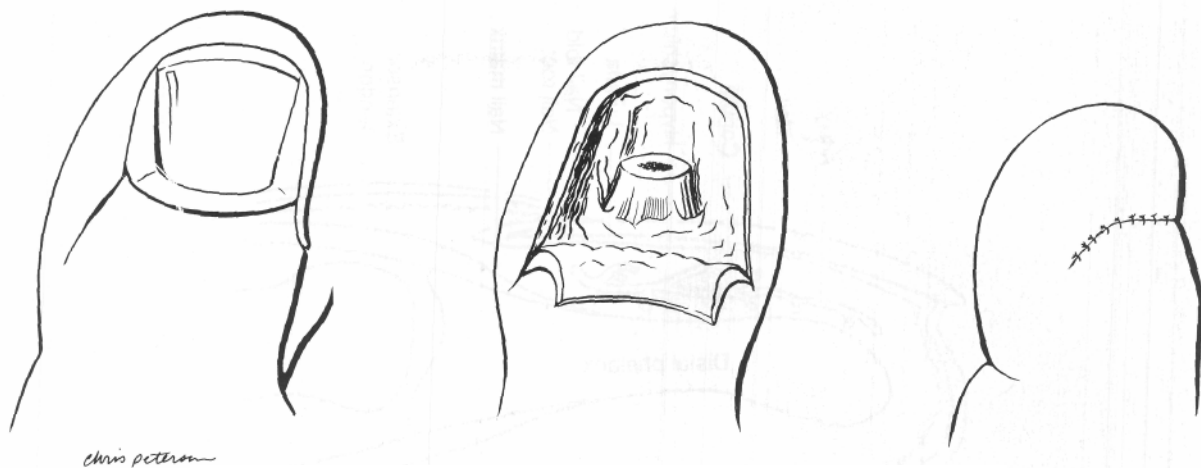


Fig. 33-15. The Lapidus procedure. (From Lapidus⁶⁴).

success rate of the treatment of fungal nails, and decrease the chance of side effects from prolonged use of medications. This method of treatment may therefore be an alternative that is much more attractive to the clinician and the patient.

A typical treatment regime for total nail avulsion with use of topical and oral antifungals involves nail avulsion and instructing the patient to begin foot soaks. Once the nail bed has stopped draining, Spectazole cream or Nizoral 2 percent cream is applied to the nail bed. The oral antifungal is started the same day as the nail avulsion, using Fulvicin P/G 330 or Nizoral. An intense history and physical examination should be performed, and the patient should not have a history of liver disease such as hepatitis or cirrhosis. Liver enzymes are monitored before nail avulsion and monitored every 3 months. Initial clinical results have been very promising (personal communication, Dr. Bruce Pichler). Other clinicians use the same basic protocol and stress the importance of a fungal culture and identification of the infecting fungus so the proper choice of topical and oral antifungal medications can be administered (personal communication, Dr. Robert Locastro).

Once again, it should be stressed that because of the risks, side effects, and long-term administration of oral antifungal medications, the patient who is considered to be a candidate for this therapy should be in good general health. Periodic monitoring of organ system

function including renal, hepatic, and hematopoietic should be performed.⁶⁷ The patient should be instructed to report any signs and symptoms that may suggest liver dysfunction, which may include unusual fatigue, anorexia, nausea, vomiting, jaundice, dark urine, and pale stools. Some clinicians will prefer to consult the patient's internist to monitor the patient's health status. Further documentation and in-depth studies may shed more light in this treatment regimen.

SUBUNGUAL EXOSTECTOMY

Many patients present to the clinic with nail pain without cryptosis of the nail borders. On reviewing radiographs, it may be discovered that the cause of the pain is a subungual exostosis that applies pressure to the nail bed from its inferior aspect (Fig. 33-16).

Debridement of the nail, if thickened and dystrophic, may bring about adequate relief. However, if the nail is normal or debridement of the dystrophic nail is ineffective, then a subungual exostectomy should be performed. The procedure entails removing the nail after suitable prepping and anesthesia and rescrubbing the surgical area. The nail bed is incised in a linear fashion directly over the subungual exostosis and parallel to the longitudinal axis of the toe. Two incisions are effected at the distal end of the linear incision at approximately a 90° angle to the linear

incision to create two flaps and expose the exostosis (Fig. 33-17).

Careful tissue handling and dissection should be stressed to keep the nail bed, nail matrix, or both intact with minimal destruction. This will hopefully

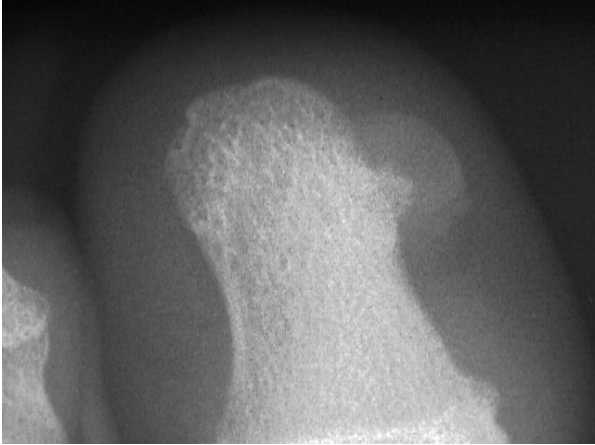


Fig.33 – 16 Subungual Exostosis

prevent further nail pathology if already present. The exostosis is removed and sent for biopsy. This area should be saucerized to prevent recurrence of the exostosis from the periosteum. Nonabsorbable sutures are used to reapproximate the nail bed and are removed in 7 to 14 days to allow regrowth of the new nail. Advantages of this procedure are no visible skin incisions and easy accessibility of the exostosis. Disadvantages are possible extensive disruption of the nail matrix or nail bed, which may lead to the formation of a dystrophic nail if not already present, or regrowth of the nail in a "shoveled" or ingrown manner.

Another approach is a fish-mouth incision at the distal end of the toe without removal of the nail to remove the exostosis. This may lead to the formation of a subungual hematoma and therefore possible nail dystrophy. Also, because the exostosis is usually very close to the nail itself, exposure and adequate resection may be difficult. Once again, it should be stressed that removal of the exostosis is important to prevent exacerbation of the curvature of the nail and prevent onychocryptosis if not already present. This procedure is performed across the country, but unfortunately there are no studies available on results.

It should also be mentioned that proximal nail groove pain can be associated with an exostosis.⁶⁸ If the patient presents with this complaint but onychocryptosis is not evident, radiographs should be taken and appropriate surgical procedures performed

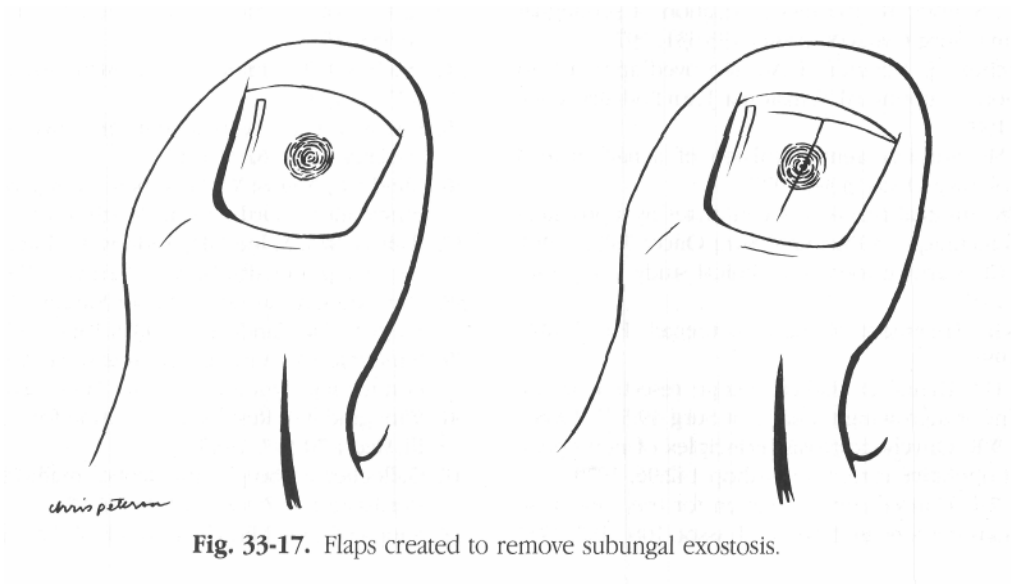


Fig. 33-17. Flaps created to remove subungual exostosis.

SUMMARY

This chapter covered nail surgery with emphasis on procedures for permanent partial and total ablation of nails. The most routinely performed procedures were discussed in depth. New trends and techniques were also covered. Further research is expected to support new trends discussed here and advance nail surgery.

REFERENCES

1. Burns SA, Ketani RS, Ketani NH: Onychocryptosis. *J Am Podiatry Assoc* 67:780, 1977
2. Fowler AW: Excision of the germinal matrix: a unified treatment for embedded toenail and onychocryptosis. *BrJ Surg* 45:382, 1958
3. Zadik FR: Obliteration of the nail bed of the great toe without shortening of the terminal phalanx. *J Bone Joint Surg Br* 32:66, 1950
4. Travers GR, Ammon RG: The sodium hydroxide chemical matricectomy procedure. *J Am Podiatry Assoc* 70:476, 1980.
5. Bouche RT: Matricectomy utilizing negative galvanic current. *Clin Podiatr Med Surg* 3:449, 1986
6. Whitney AK: An illustrated labiomatricectomy procedure. *J Am Podiatry Assoc* 57:169, 1967
7. Weisfeld M: Illustrated technique for the complete removal of nail matrix and hyponychium without skin incisions (Suppan nail technique n. 2). *J Am Podiatry Assoc* 65:481, 1975
8. Wee GC, Shieber W: Painless evacuation of subungual hematoma. *Surg Gynecol Obstet* 133:531, 1970
9. Palamarchuk HJ, Kerzner M: An improved approach to evacuation of subungual hematoma. *J Am Podiatry Assoc* 79:566, 1989
10. Albom MJ: Surgical gems: avulsion of a nail plate. *J Dermatol Surg Oncol* 3:34, 1977
11. Scher RK: Surgical avulsion of nail plates by a proximal to distal technique. *J Dermatol Surg Oncol* 7:296, 1981
12. Heifetz CJ: Ingrown toenail: a clinical study. *Am J Surg* 38:298, 1937
13. Dixon GL: Treatment of ingrown toenail. *Foot Ankle* 3:254, 1983
14. Herold HZ, Danial D: Radical wedge resection in the treatment of ingrowing toenail. *Int Surg* 49:558, 1968
15. Murray WR: Onychocryptosis. Principles of non-operative and operative care. *Clin Orthop* 142:96, 1979
16. Bartlett RW: Conservative operation for the cure of so called ingrown toenail. *J Am Med Assoc* 108:1257, 1937
17. Frost LA: Root resection for incurvated nail. *J Am Podiatry Assoc* 40:19, 1950
18. Perlman P: Don't take two aspirin. Johnson Publishing Company, Boulder, CO, 1982
19. Vandenbos KQ, Bowers WF: Ingrowing toenail: results of weight bearing on soft tissue. *US Armed Forces MedJ* 10:1168, 1959
20. DuVries HL: Ingrown nail. *Chiropody Rec* 27:155, 1944
21. DuVries HL: Hypertrophy of unguilabia. *Chiropody Rec* 16:13, 1933
22. Newman RW: A simplified treatment of ingrown toenail. *Surg Gynecol Obstet* 89:638, 1949
23. Polokoff M: Ingrown toenail and hypertrophied nail lip surgery by electrolysis. *J Am Podiatry Assoc* 51:805, 1961
24. Frost L: A definite surgical treatment for some lateral nail problems. *J Nat Assoc Chiropodists* 47:493, 1957
25. Yale JF: Podiatric Medicine. 3rd Ed. Williams & Wilkins, Baltimore, 1987
26. Palmer BV, Jones A: Ingrowing toenails: the results of treatment. *BrJ Surg* 66:575, 1979
27. Murray WR, Bedi BS: The surgical management of ingrowing toenail. *BrJ Surg* 62:409, 1975
28. Steinberg MD: A simplified technique for the surgery of ingrowing nails. *Surgery* 36:1132, 1954
29. Perrone MA: Nail matricectomy by onychotripsy with airmotor. *J Am Podiatry Assoc* 60:92, 1970
30. Silverman SH: Cryosurgery for ingrowing toenail. *J R Coll Surg Edinb* 29:289, 1984
31. Vernon S: Ingrown toenail: operation by electrosurgery. *AmJ Surg* 42:396, 1938
32. Dinesh D: Ingrowing toenail (letter to the editor). *NZ MedJ* 89:494, 1979
33. Gardner P: Negative galvanic current in the surgical correction of onychocryptotic nails. *J Am Podiatry Assoc* 48:555, 1958
34. Linch AO: Treatment of ingrowing toenail. *South Surg* 8:173, 1939
35. Farnsworth FC: A treatment for convoluted nails. *J Am Podiatry Assoc* 62:110, 1972
36. Ilfeld FW, August W: Treatment of ingrown toenail with plastic insert. *Orthop Clin North Am* 5:95, 1974
37. Wallace WA, Milne DD, Andrew T: Gutter treatment for ingrowing toenails. *Br MedJ* 2:168, 1979
38. Mercado OA: An Atlas of Foot Surgery. Vol. 1. Forefoot Surgery. Carolando Press, Oak Park, 1979
39. Winograd AM: A modification in the technique of operation for ingrown toenail. *J Am Med Assoc* 91:229, 1929
40. Winograd AM: Results in operation for ingrown toenail. *Ill MedJ* 70:197, 1936
41. Gallocher J: The phenol alcohol method of nail matrix sterilisation. *NZ MedJ* 86:140, 1977
42. Suppan RJ, Ritchlin JD: A non-disabling surgical pro-

- cedure for ingrown toenail. *J Am Podiatry Assoc* 52:900, 1962
43. Robb JE, Murray WR: Phenol cauterization in the management of ingrowing toenails. *Scott MedJ* 27:236, 1982
44. Ross WR: Treatment of the ingrown toenail. *Surg Clin North Am* 49:1499, 1969
45. Shepherdson A: Nail matrix phenolization: a preferred alternative to surgical excision. *Practitioner* 219:725, 1977
46. Drago JJ, Jacobs AM, Oloff L: A comparative study of postoperative care with phenol nail procedures. *J Foot Surg* 22:332, 1983
47. McGlamry ED: Management of painful toes from distorted toenails. *J Dermatol Surg Oncol* 5:554, 1979
48. Yale JF: Phenol-alcohol technique for correction of infected ingrown toenail. *J Am Podiatry Assoc* 64:46, 1974
49. Greenwald L, Robbins HM: The chemical matricectomy. *J Am Podiatry Assoc* 71:388, 1981
50. Cooper C: Phenol-alcohol nail procedure: post-operative care. *J Am Podiatry Assoc* 55:661, 1965
51. Fulp M, McGlamry ED: New enzyme aids phenol technique in nail surgery. *J Am Podiatry Assoc* 62:395, 1972
52. Acker I: Preventing the postoperative sequelae to phenolization of nail bed and matrix. *J Am Podiatry Assoc* 58:351, 1968
53. Anton-Athens V, Ketai DL: Use of cortisporin otic solution in phenol nail surgery. *J Am Podiatric Med Assoc* 75:31, 1985
54. Rinaldi R, Sabia M, Gross J: The treatment and prevention of infection in phenol alcohol matricectomies. *J Am Podiatry Assoc* 72:435, 1982
55. Brown FC: Chemocautery for ingrown toenails. *J Dermatol Surg Oncol* 7:331, 1981
56. Apfelberg DB, Rothermel E, Widtfeldt A, et al: Progress report on use of carbon dioxide laser for nail disorders. *Curr Podiatry* 32:29, 1983
57. Borovoy M, Fuller TA, Holtz P, Kaczander BI: Laser surgery in podiatric medicine present and future. *J Foot Surg* 22:353, 1983
58. Farber EM, South DA: Urea ointment in the nonsurgical avulsion of nail dystrophies. *Cutis* 22:689, 1978
59. Whitney AK: Total matricectomy procedure. *J Am Podiatry Assoc* 58:157, 1968
60. Robb JE: The results of surgery for nail dystrophy of the hallux in children. *Surg Infancy Child* 39:131, 1984.
61. Kaplan EG: Elimination of onychauxis by surgery. *J Am Podiatry Assoc* 50:111, 1960
62. Mercado OA, Dalianis G, Chulengarian J, et al: Kaplan nail revisited. *Curr Podiatry* 21:21, 1972
63. Field LM: An ultimate solution for a painful toe. *J Dermatol Surg Oncol* 5:402, 1979
64. Lapidus PW: Complete and permanent removal of toenail in onychogryphosis and subungual osteoma. *Am J Surg* 19:92, 1933
65. Gastwirth BW, Anton V, Martin RA: The terminal Syme procedure. *J Foot Surg* 20:95, 1981
66. Hettinger DF, Valinsky MS: Treatment of onychomycosis with nail avulsion and topical ketoconazole. *J Am Podiatr Med Assoc* 81:28, 1991
67. 1991 Physicians' Desk Reference. 45th Ed. p. 1119. Medical Economics Data, Montvale, NJ, 1991.
68. Chinn S, Jenkin W: Proximal nail groove pain associated with an exostosis. *J Am Podiatr Med Assoc* 76:506, 1986